

Guidelines for management of solitary pulmonary nodules

Scope of the guideline

This guidance has been produced to support the following:

The investigation of patients found to have a solitary non-calcified pulmonary nodule on computed tomographic (CT) scanning of the chest. These guidelines are for patients 35 years or older with a newly detected indeterminate pulmonary nodule. They do **not** apply to pulmonary nodules identified in patients with known malignancy.

Guideline background

Lung nodules are detected very commonly on CT scans of the chest, and the ability to detect very small nodules improves with each new generation of CT scanner. During the past 5 years, new information regarding prevalence, characteristics, and growth rates of small lung cancers has become available. This guideline has been written in response to this. Its aim is to provide practical guidelines for the management of small pulmonary nodules that are detected during the course of CT examinations performed for purposes other than lung cancer screening.

Guideline statements

Nodules smaller than 8mm¹

Nodule size (mm) [*]	Low-Risk Patient [†]	High-Risk Patient [‡]
≤ 4	No follow-up needed	Repeat CT at 12 mo If unchanged no further follow-up
>4-6	Repeat CT at 12 mo If unchanged no further follow-up	Repeat CT at 12 mo then at 24 mo if no change
>6-8	Repeat CT at 12 mo then at 24 mo if no change	Repeat CT at 6 mo then at 12 and 24 mo if no change

* Average length and width

† Minimal or absent smoking history or other risk factors

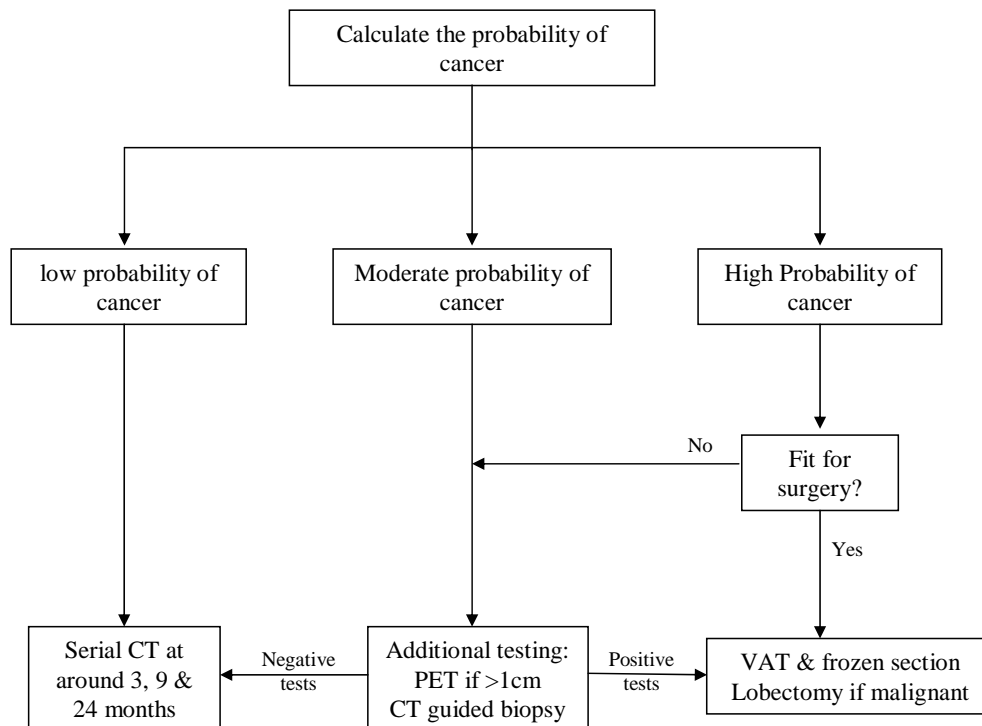
‡ History of smoking or other risk factors

Nodules 8mm to 30mm in size²

Assess the risk of cancer. This can now be calculated using a model (see separate Excel spreadsheet).

	Low risk	Intermediate	High
Nodule size	8-14mm	15-22mm	23-30mm
Age	< 45	45-60	> 60
Smoking	Never	Current	Current
Nodule margin	Smooth	Scalloped	Spiculated

Follow the algorithm shown below:



Monitoring of the guideline

Compliance with guideline will be considered as a topic for audit by the NSSG in 2008.

References

1. MacMahon et al. Guidelines for Management of Small Pulmonary Nodules Detected on CT Scans: A Statement from the Fleischner Society. *Radiology* 2005; 237:395–400
2. Ost et al. The Solitary Pulmonary Nodule. *N Eng J Med* 2003; 348:2535-42

Authors

- Ian Woolhouse
- John Reynolds

Update in conjunction with Dr Ben Holloway, consultant radiologist UHBFT Oct 2009.